

*Case Report***Amelogenesis imperfecta, nephrocalcinosis, and hypocalciuria syndrome in two siblings from a large family with consanguineous parents**Emma L. Dellow¹, Kathryn E. Harley², Robert J. Unwin¹, Oliver Wrong¹, Gerald B. Winter² and Brian J. Parkins³¹Centre for Nephrology and Institute of Urology and Nephrology, The Middlesex Hospital, Royal Free and University College Medical School and ²Eastman Dental Hospital and Institute, ³57 Portland Place, London**Key words:** amelogenesis imperfecta; nephrocalcinosis; hypocalciuria; autosomal recessive; matrix proteins; renal failure**Introduction**

The syndrome of amelogenesis imperfecta and nephrocalcinosis has been previously documented in three sibling pairs. Here we describe two siblings from a large family. The parents were first cousins, and this is the first time the condition has been documented in offspring of a consanguineous marriage, supporting the belief that inheritance is autosomal recessive.

Amelogenesis imperfecta is a term used to describe inherited defects of tooth enamel [1]. It most commonly has an autosomal dominant pattern of inheritance, but autosomal recessive, X-linked, and sporadic cases also occur. The condition has also been previously shown to occur as part of several multi-organ syndromes including (i) amelogenesis imperfecta and hypothalamo-hypophyseal insufficiency, (ii) cone-rod dystrophy and amelogenesis imperfecta, and (iii) amelogenesis imperfecta and nephrocalcinosis. In these families, described below, nephrocalcinosis was diagnosed only after the children had already received dental treatment for their amelogenesis imperfecta.

The first family, described in 1972 by MacGibbon [2], comprised a brother and sister, the sister being diagnosed by screening after her much older brother developed renal failure and hypertension. It was noted that both siblings had the same defect of dental enamel. The older sibling died at the age of 26, possibly as a result of complications arising from his nephrocalcinosis. The sister went on to develop multiple urinary infections, hypertension and renal failure.

The second pedigree, described by Lubinsky *et al.*

in 1985 [3], was another brother and sister pair who presented in their first decade with amelogenesis imperfecta, enuresis, and intermittent urinary infections. Both had nephrocalcinosis and clinically undetectable tooth enamel with failure of the majority of the permanent teeth to erupt. Their amelogenesis imperfecta was described as being phenotypically similar to autosomal recessive hypoplastic (enamel agenesis) amelogenesis imperfecta [4] with dagger-shaped intrapulpal calcification also present in some teeth. In both patients, serum electrolytes, pH, bicarbonate, PTH, calcitonin, 25(OH) vitamin D, calcium, phosphate, and alkaline phosphatase were normal. Both demonstrated decreased urinary concentrating ability and the boy had a decreased creatinine clearance. Both had low urinary excretion of calcium and phosphate and increased urinary osteocalcin.

More recently, Phakey *et al.* described another sibling pair with autosomal recessive hypoplastic (enamel agenesis), amelogenesis imperfecta, and nephrocalcinosis [5,6]. Both had normal calcium metabolism and the boy had serum creatinine at the upper limit of normal. Normal urinary osteocalcin levels were found in both children and both had normal 24-h urinary excretion of calcium and phosphate. Electron microscopical study of the teeth of these cases was performed and showed the presence of hypoplasia and hypomaturation/hypocalcification in the same tooth, suggesting defects in the secretory and maturation phases of amelogenesis. The authors suggested that the defect may lie with one of the matrix proteins and that two closely related genes might be involved, rather than a single gene.

In none of these previously described families with amelogenesis imperfecta and nephrocalcinosis has there been any family history of amelogenesis imperfecta and none of the parents have been related.

Cases

Our sibling pair are a sister and brother whose parents were first cousins [7]. Neither parent had any history

Correspondence and offprint requests to: Professor Robert Unwin, Centre for Nephrology and Institute of Urology and Nephrology, The Middlesex Hospital, Royal Free and University College Medical School, 48 Riding House Street, London W1P 7PN, UK.

of renal impairment or nephrocalcinosis. The father's dental records show he had extensive dental work; however, this was for age-related dental disease and not for amelogenesis imperfecta. None of the other five siblings or the mother has evidence of amelogenesis imperfecta. All of them have normal renal ultrasound scans with no evidence of nephrocalcinosis. The four children of the two index cases are unaffected by amelogenesis imperfecta.

When the sister was 12 and the brother 8 years old, both children were treated at the Eastman Dental Hospital, where they were noted to have extremely thin and smooth enamel affecting both primary and erupted permanent teeth. In the brother, the colour of the remaining primary teeth appeared normal, but the erupted permanent incisor teeth were discoloured light yellow. The incisor and canine teeth in the sister were similarly discoloured light yellow, whereas the premolars and molars were yellowish-brown in colour. The teeth in both children were widely spaced and their molar and premolar cusps were sharp and the incisal enamel razor-edged. A number of erupted permanent teeth in both children showed evidence of pre-eruptive coronal resorption. Intraoral radiographs of the brother showed only minute traces of enamel and pre-eruptive coronal resorption of a number of posterior teeth (Figure 1). In the sister, radiographs showed little evidence of the extremely thin enamel, marked coronal resorption of the unerupted maxillary first molars, and less extensive coronal resorption of other unerupted premolar and molar teeth. A notable feature in both sets of radiographs was what appeared to be intrapulpal calcification limited to some primary teeth and mandibular permanent incisors in the brother, but affecting all teeth in the sister, whether erupted or unerupted. This was not confirmed histologically. Later, both had extensive bridgework and crowns fitted to all erupted permanent teeth. As an adult, the brother required further reconstruction and removal of an

upper right premolar which had eroded through the mucous membrane, beneath the bridgework. Eight of thirteen teeth used to support the bridgework required root canal treatment, an unusually high proportion.

The brother had nephrocalcinosis diagnosed at age 32, following a routine medical screen (Figure 2). He was referred to us aged 36 with polyuria and polydipsia. He had recently passed a renal calculus; however, no stones were subsequently found in his urine. He gave no history of urinary-tract infection or childhood enuresis. Renal ultrasound revealed asymmetrical kidneys, the left 12.4 cm and the right 6.7 cm, with multiple cysts and bright parenchyma. Isotope renogram showed the right kidney to be unobstructed, but contributing only 9% to function, and the left 91%. It is thought he may have had chronic pyelonephritis as a child. He has slight renal impairment, plasma creatinine having reached a peak of 161 $\mu\text{mol/l}$ (normal range 50–125), with creatinine clearance of 76 ml/min. Plasma calcium is normal at 2.46 mmol/l (2.2–2.6), plasma inorganic phosphate is 0.92 mmol/l (0.7–1.5), and alkaline phosphatase 234 IU/l, with normal PTH and 25(OH) vitamin D₃. He has proteinuria of 1 g/24 h, normal urinary citrate and oxalate, and normal urinary amino acids apart from strong taurine and an unidentified ninhydrin-positive species. Urinary calcium is reduced at 0.9 mmol/24 h (2.0–9.0), consistent with previous cases, with normal urinary phosphate excretion of 24 mmol/24 h (15–50). A water deprivation test performed in 1990 produced a urinary osmolality of 493 (significantly reduced). A random urine pH, measured with a glass electrode, was 5.76. This subject also has hypercholesterolaemia, with serum cholesterol of 7.2 mmol/l at commencement of lipid-lowering therapy.

His older sister was seen by us aged 40 after her brother revealed they both had the same dental problems as children. Her nephrocalcinosis had originally been diagnosed following a urinary infection during

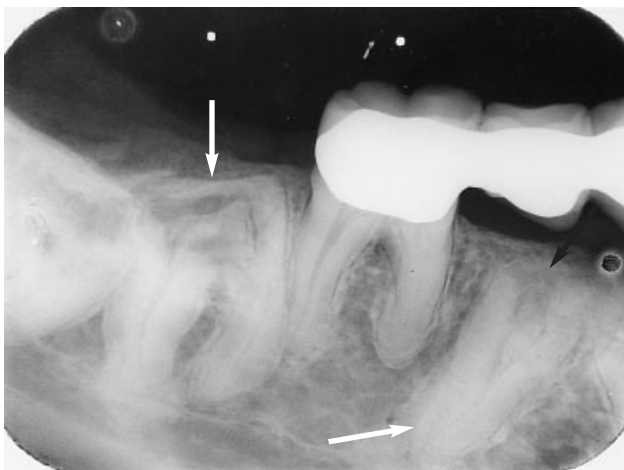


Fig. 1. An intraoral radiograph from the brother demonstrating the presence of unerupted teeth (open arrows) affected by hypoplastic amelogenesis imperfecta, with characteristic extensive coronal resorption and probable intrapulpal calcification (closed arrow).

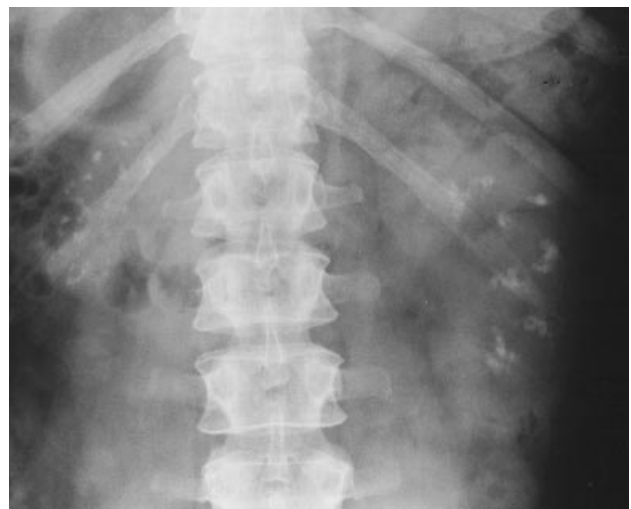

Fig. 2. Plain abdominal radiograph showing extensive nephrocalcinosis in a medullary distribution, with a small right kidney in the brother.

her first pregnancy aged 26. She had had no particular problems apart from infrequent urinary infections, and hypertension. Renal ultrasound scan and intravenous pyelogram both show normal-sized kidneys with multiple hyperechoic foci. Plain abdominal film shows multiple small calcifications of approximately 2–3 mm in both kidneys. These appearances have remained unchanged over the period of her follow-up. Plasma creatinine was up to 89 $\mu\text{mol/l}$ with creatinine clearance of 90 ml/min. Plasma calcium is normal but plasma phosphate is reduced, having been 0.46 mmol/l at one point, with a maximum level of only 0.71 mmol/l (0.7–1.5). Plasma 25(OH) vitamin D3 is normal at 13 $\mu\text{g/l}$ (3–30), but PTH is elevated at 13.3 pmol/l (1.0–6.5). Bone mineral density is normal when assessed by isotopic densitometry. Urine biochemistry showed a normal amino-acid screen. Urine calcium excretion is also reduced at 0.5 mmol/24 h, with normal urine phosphate. Urine oxalate and citrate are both normal but there is proteinuria of 0.18 g/24 h (<0.06).

Discussion

The syndrome of amelogenesis imperfecta and nephrocalcinosis has been previously described predominantly in children. Our family are therefore unusual in that their renal involvement was not detected until they were well into adulthood, and they have had a relatively benign course. The only characteristics common to all cases appear to be failure of teeth to erupt, with thin or absent enamel, bilateral nephrocalcinosis in a medullary distribution, and normal plasma calcium, 25(OH) vitamin D3, and alkaline phosphatase. Varying degrees of renal impairment and urinary concentrating ability have been described.

Nephrocalcinosis may remain undetected until patients present with recurrent urinary infections, pyelonephritis, or the passage of a stone. In this condition the ultrasound and radiographic appearances of the nephrocalcinosis are indistinguishable from other causes of medullary nephrocalcinosis; in fact, the brother was originally referred as a possible case of medullary sponge kidney. The fact that this sibling pair are offspring of a consanguineous marriage also confirms the autosomal recessive inheritance of this condition. Autosomal recessive forms of amelogenesis imperfecta make up less than 10% of all forms of amelogenesis imperfecta. Although, in this condition the amelogenesis imperfecta is described as being of enamel agenesis type, strictly speaking the enamel is severely hypoplastic.

Much work has been done over the last 10 years to define the genetic defects underlying amelogenesis imperfecta. The X-linked form has been extensively investigated and has been characterized as a defect in the amelogenin gene in the Xp22 region [1,8]. There is also an amelogenin gene in the peri-centromere region of the Y chromosome which appears to be transcribed in less than 10% of normal males. Males

and females with the condition exhibit differing phenotypes due to Lyonization in females [9].

There are at least two forms of autosomal dominant amelogenesis imperfecta, one of which has been localized to the long arm of chromosome 4 [10,11], which appears to be an area carrying many genes involved in the formation and maintenance of mineralized tissues, including the ameloblastin gene [12,13], which is considered a possible candidate for autosomal dominant amelogenesis imperfecta. Other structural genes in this area include osteopontin, albumin, and bone sialoprotein.

Another candidate for autosomal dominant amelogenesis imperfecta is the tuftelin gene on chromosome 1 q 21–31 [14]. This is also the chromosome carrying the gene for osteocalcin, which Lubinsky found to be elevated in his patients' urine. None of the proteins known to be involved in amelogenesis (amelogenin, ameloblastin, and tuftelin) has been shown to be expressed in the kidney. Other proteins known to be involved in tooth mineralization, including albumin and osteopontin [15], also occur in the kidney.

Albumin appears to make up the majority of protein in renal stones, whereas osteopontin appears to be a major inhibitor of crystal nucleation in renal-stone formation, particularly calcium oxalate stones [16,17]. This is in contrast to its role in the mineralization of teeth, where it appears to be responsible for the initiation of calcification at the dentinocementum junction. Osteopontin has not been found in enamel. Expression of osteopontin in the kidney appears to be widespread. It has been postulated that osteopontin may be involved in the pathogenesis of tubulointerstitial injury following glomerulonephritis. It binds avidly to macrophages *in vitro*, and Pichler *et al.* [18] found that the expression of osteopontin in the kidney preceded tubular damage and that infiltrating monocyte/macrophages localized to areas of osteopontin expression. Osteopontin and osteocalcin are both matrix proteins, the genes for which are carried on the same chromosome as other genes coding for proteins involved in amelogenesis. This may prove to be an interesting area for investigation in trying to classify the genetic defect behind amelogenesis imperfecta and nephrocalcinosis.

Histologically detectable nephrocalcinosis has been reported as an incidental finding in up to 100% of autopsies. Radiographically detectable nephrocalcinosis is much less common [7]. This syndrome therefore seems to combine one uncommon condition (amelogenesis imperfecta) with one much less common (nephrocalcinosis). Further research into this area may help to shed light not only on the pathogenesis of the syndrome itself, but also on to the pathogenesis of the two individual conditions which make up the whole. This is important, particularly given the morbidity associated with unrecognized and untreated nephrocalcinosis.

Although this syndrome appears to be extremely rare, the medical and psychological significance is high. Children born with amelogenesis imperfecta have a dentally disfiguring condition, often requiring extensive

cosmetic and restorative dentistry. Historically it was not uncommon for treatment to necessitate a full mouth clearance and complete dentures in order to achieve a good cosmetic result. MacGibbon's patients show that the consequences of ignoring possible renal involvement can be quite serious.

Although the brother has stable renal function and his blood pressure is well controlled, he is at risk of developing end-stage renal failure at a later date, and both he and his sister are at risk of recurrent urinary infections. Any patient with apparently autosomal recessive hypoplastic amelogenesis imperfecta should at least have a renal ultrasound performed, to exclude nephrocalcinosis, as this test is both non-invasive and involves no exposure to ionizing radiation.

We would like to hear from any other groups who may have similar patients with this condition.

References

- Bäckman B. Inherited enamel defects. In: Chadwick DJ, Cardew G, ed. *Dental Enamel* (Ciba Foundation Symposium 205). John Wiley, Chichester, UK. 1997; 175–186
- MacGibbon D. Generalised enamel hypoplasia and renal dysfunction. *Aust Dent J* 1972; 17: 61–63
- Lubinsky M, Angle C, Marsh W, Witkop CJ. Syndrome of amelogenesis imperfecta, nephrocalcinosis, impaired renal concentration, and possible abnormality of calcium metabolism. *Am J Med Genet* 1985; 20: 233–243
- Witkop CJR. Amelogenesis imperfecta, dentinogenesis imperfecta and dentin dysplasia revisited: problems in classification. *J Oral Pathol* 1989; 17: 547–553
- Phakey P, Palamara J, Hall RK, McCredie DA. Ultrastructural study of tooth enamel with amelogenesis imperfecta in Al-nephrocalcinosis syndrome. *Connect Tissue Res* 1995; 32 (1–4): 253–258
- Hall RK, Phakey P, Palamara J, McCredie D. Amelogenesis imperfecta and nephrocalcinosis syndrome. *Oral Surg Oral Med Oral Pathol* 1995; 79 (5): 583–593
- Wrong O. Nephrocalcinosis. In: Davison AM, Cameron JS, Grunfeld J, Kerr DNS, Ritz E, Winearls CG, ed. *Oxford Textbook of Clinical Nephrology*. 2nd edn, vol. 2. Oxford University Press, Oxford, 1998; 1375–1396
- Collier PM, Sauk JJ, Rosenbloom J, Yuan ZA, Gibson CW. An amelogenin gene defect associated with human X-linked amelogenesis imperfecta. *Arch Oral Biol* 1997; 42 (3): 235–242
- Lench NJ, Winter GB. Characterisation of molecular defects in X-linked amelogenesis imperfecta (AIH1). *Hum Mutat* 1995; 5: 251–259
- Forsman K, Lind L, Bäckman B, Westermark E, Holmgren G. Localisation of a gene for autosomal dominant amelogenesis imperfecta (ADAI) to chromosome 4q. *Hum Mol Genet* 1994; 3(9): 1621–1625
- Karrman C, Bäckman B, Holmgren G, Forsman K. Genetic heterogeneity of autosomal dominant amelogenesis imperfecta demonstrated by its exclusion from the AIH2 region on chromosome 4Q. *Arch Oral Biol* 1995; 41(8/9): 893–900
- Deutsch D, Catalano-Sherman J, Dafni L, David S, Palomon A. Enamel matrix proteins and ameloblast biology. *Connect Tissue Res* 1995; 32 (1–4): 97–107
- Kresbach PH, Lee SK, Matsuki Y *et al.* Full-length sequence, localisation, and chromosome mapping of ameloblastin. *J Biol Chem* 1996; 271 (8): 4431–4435
- Gehron Robey P. Vertebrate mineralised proteins: structure and function. *Connect Tissue Res* 1996; 35(1–4): 185–190
- Young MF, Kerr JM, Termine JD *et al.* cDNA cloning, mRNA distribution and heterogeneity, chromosomal location and RFLP analysis of human osteopontin. *Genomics* 1990; 7: 491–502
- Lieske JC, Toback FG. Interaction of urinary crystals with renal epithelial cells in the pathogenesis of nephrolithiasis. *Semin Nephrol* 1996; 16 (5): 458–473
- McKee MD, Nanci A, Khan SR. Ultrastructural immunodetection of osteopontin and osteocalcin as major matrix components of renal calculi. *J Bone Miner Res* 1995; 10 (12): 1913–1923
- Pichler R, Giachelli CM, Lombardi D *et al.* Tubulointerstitial disease in glomerulonephritis; potential role of osteopontin (uropontin). *Am J Pathol* 1994; 44 (5): 915–929

Received for publication: 17.7.98

Accepted: 22.7.98